

## Case Report - Tissue Regeneration

# Regeneration of mandibular ameloblastoma defect with the help of autologous dental pulp stem cells and buccal pad of fat stromal vascular fraction

### Access this article online

#### Website:

[www.amsjournal.com](http://www.amsjournal.com)

#### DOI:

10.4103/2231-0746.186128

#### Quick Response Code:



K. Manimaran, Rohini Sharma<sup>1</sup>, S. Sankaranarayanan<sup>1</sup>, S. Mahendra Perumal

Department of Oral and Maxillofacial Surgery, K.S.R. Institute of Dental Science and Research, Tiruchengode, <sup>1</sup>Laboratory of Cell Culture, Mother Cell Regenerative Centre, Trichy, Tamil Nadu, India

#### Address for correspondence:

Dr. S. Sankaranarayanan, Director, Mother Cell Regenerative Center, Trichy - 620 017, Tamil Nadu, India.

E-mail: [stemcellsankar@gmail.com](mailto:stemcellsankar@gmail.com)

## ABSTRACT

Ameloblastoma is benign odontogenic tumor, which is locally aggressive in behavior. Till date, the treatment of choice is resection and reconstruction using a variety of modalities. Inadequate resection may lead to many complications such as bone deformity and dysfunction. This report is about a 14-year-old male with ameloblastoma treated with autologous dental pulp stem cells (DPSCs) and stromal vascular fraction (SVF) and evidence of bone regeneration. Marsupialization was performed; tooth was extracted and sent for DPSC cultivation. On the day of surgery, SVF was processed from buccal pad of fat, and platelet-rich fibrin (PRF) was prepared from patient's peripheral blood. During the procedure, labial plate resection and curating of tumor lining were done. After which, a mesh packed with SyboGraft T-plug, prepared SVF, DPSCs, and PRF were placed over lingual cortex and pressure dressing was done. After the 1<sup>st</sup> month of surgery the postoperative course was uneventful, the wound shrinkage led to exposure of mesh in the intraoral region. Removal of exposed mesh was done. The correction surgery with removal of part of mesh and primary closure was achieved with SyboGraft plug, SVF and PRF. Enhanced bone formation was seen in post-operative OPG and CT Scan after 10<sup>th</sup> month. In this article, we propose an innovative approach to manage these cases by using a combination of autologous DPSC and buccal pad of fat SVF to regenerate a mandibular defect left by the resection of an ameloblastoma with 1.5 year follow-up. We were able to demonstrate bone regeneration using this technique with no recurrence of tumor.

**Keywords:** Ameloblastoma, buccal pad of fat, dental pulp stem cell, mandibular regeneration, stromal vascular fraction

## INTRODUCTION

Ameloblastoma is the most common clinically significant odontogenic tumor. It accounts for 11% of all odontogenic tumors. The lesion has a high recurrence rate and if not treated, it can increase significantly in size, resulting in severe facial dysmorphology and functional disability. The established literature supports two therapeutic options: Radical resection or conservative treatment such as enucleation.<sup>[1,2]</sup> The principal treatment for ameloblastoma is resection, and an inadequate resection could lead to

This is an open access article distributed under the terms of the Creative Commons Attribution-NonCommercial-ShareAlike 3.0 License, which allows others to remix, tweak, and build upon the work non-commercially, as long as the author is credited and the new creations are licensed under the identical terms.

**For reprints contact:** [reprints@medknow.com](mailto:reprints@medknow.com)

**Cite this article as:** Manimaran K, Sharma R, Sankaranarayanan S, Perumal SM. Regeneration of mandibular ameloblastoma defect with the help of autologous dental pulp stem cells and buccal pad of fat stromal vascular fraction. *Ann Maxillofac Surg* 2016;6:97-100.

recurrence. Resection of the mandible may lead to a number of complications such as loss of bone deformity, dysfunction, and psychological distress, even though the patient undergoes reconstruction.<sup>[3]</sup> To the best of our knowledge, this is the first case that demonstrated successful bone formation with the use of autologous dental pulp stem cells (DPSCs) and fat stromal vascular fraction (SVF) derived from the buccal fat pad. This study was approved by the Local Ethics Committee of the K.S.R Institute of Dental Science and Research, Tiruchengode, Tamil Nadu, India.

## CASE REPORT

A 14-year-old male reported to the Department of Oral & Maxillofacial Surgery at K.S.R Institute of Dental Science and Research, Tiruchengode, Tamil Nadu, India, with the complaint of small swelling in the anterior mandibular region. This was diagnosed as unicystic ameloblastoma with the help of a biopsy. The patient was lost to follow-up for 1 year. He presented with defined extraoral swelling of the right side of the body of the mandible, which was about 3 cm × 3 cm and extended from the corner of the lip to 1 cm below the lower border of the mandible. Skin over the swelling was normal [Figure 1a]. On palpation, the mass was firm to hard in consistency, with no pulsation, nontender, and not compressible. Intraorally also, there was large swelling which was about 2 cm × 5 cm and it was attached to the gingiva from the right lower second molar (47) to the left lower canine (33) with obliteration of the sulcus [Figure 1b].

The orthopantomogram (OPG) revealed a well-defined radiolucent area extending from the left lower lateral incisor (32) to the right lower second premolar (45) of about 3 cm × 3 cm dimension with an impacted canine tooth 43 seen at the apex of tooth 45 and impacted 32 seen on the left side inferior border of mandible [Figure 2a]. A three-dimensional computed tomography (CT) scan of the mandible was taken and showed expansion of both buccal and lingual cortical plates of mandible with perforation [Figure 2b, c and d].

The treatment was performed in the following steps:

1. Marsupialization was performed in the area of the lesion, and the opening was maintained for 2 weeks' time. Surgical site got infected postoperatively, which was controlled within 2 weeks' time
2. Extraction of tooth numbers 45, 44, 42, 41, and 31 and primary closure was done. On the same day, removal of upper right first premolar (14) which was a normal vital tooth was washed in normal saline. The tooth was immediately placed into transport media containing phosphate-buffered saline (PBS) (PBS; Sigma Chemical, St. Louis, MO, USA) in a sterile container and stored in a refrigerator. The tooth in transport material was transported to the Mother Cell Regenerative Centre laboratory at Trichy in an ice bag (within 5 h)
3. In the laboratory, 4.5 million stem cells were separated from the dental pulp of the right first premolar tooth 14 and placed into culture media. Four to five weeks were needed for culturing stem cell from DPSC which yielded 20 million cells.
4. After culturing, the stem cells were stored in the laboratory until the day of surgery
5. The patient was operated under general anesthesia. Fat from the buccal pad of the left side of the cheek was harvested which yielded 15 gms of fat. The fat was transferred to the laboratory in the Bio-technology Department for processing. A total of 45 million cells from the SVF contains mesenchymal progenitor cells, precursor cells, and fat stem cells.<sup>[4]</sup> The processing time was 3 hour
6. An extraoral approach was planned. The skin incision was placed from the left to the right submandibular region. Layer-by-layer dissection was carried out, and lower border of mandible and buccal cortical plate from the right side angle to the left side first premolar region were exposed. The affected buccal cortical plate from lesional area from 46 to 33 regions was removed [Figure 3]. The lining of the lesion curetted and removed along with the impacted teeth 43 and 32. The lower border of the mandible was maintained and lingual cortical plate was not disturbed even in the perforated area [Figure 3a and b]. Titanium mesh was adapted to the buccal side and lower border of mandible from 47 to 33 regions. The height of the buccal side of the mesh was less than the lingual cortical plate and a 1 cm of gap was maintained between lingual cortical plate and the mesh from 47 to 33 regions [Figure 3c]. The mesh was taken out to allow placing of the grafts
7. Before placing the mesh over the operated area, five Sybografts (SyboGraft-T-plug is a sterile synthetic β-tricalcium phosphate-Eucare Pharmaceuticals (P) Ltd., Chennai, India) scaffold measuring 25 mm in length with a diameter of 12 mm were placed inside the mesh and fixed with resorbable sutures [Figure 3d]. The prepared 20 million stem cells cultured from DPSC and the fat SVF containing 45 million cells mixed with platelet-rich plasma (PRP) were placed over the graft [Figure 4a and b]. The stem cells were mixed with the granules and were packed inside the mesh and placed over the lingual cortex [Figure 4c and d]. Platelet-rich fibrin (PRF) that was prepared during the procedure was also packed inside the mesh. The packed mesh was placed over the mandible and retained with screws at both ends. The wound was closed in layers. No drains were placed extraorally, and a pressure dressing was placed over the submandibular region. The postoperative period was uneventful
8. Excised specimens were sent for biopsy and confirmed the unicystic ameloblastoma. After 1<sup>st</sup> month of surgery, the intraoral part of the mesh was exposed due to shrinkage of the wound. Antibiotics were given for 3 days, and an intraoral incision was made in the buccal sulcus from the right retromolar region to the left premolar region to expose the mesh under local anesthesia. Approximately, 1 cm of the mesh was removed near the lower border of the mandible. Some loose graft material and granulation tissue were also removed from the operated area. During the procedure, buccal pad of fat was harvested from the right side for SVF preparation. SVF prepared from the buccal pad of fat was mixed with PRP and placed in the defect area of the mandible with 2 sybo graft plug (25 mm × 12 mm in diameter). PRF was also placed over the graft material to enhance healing process. Primary

closure was achieved. Postoperative days were uneventful. Postoperative OPG and CT scan of the mandible were taken during the 10 months, it showed satisfactory bone formation [Figure 5].

## DISCUSSION

Numerous modalities of treatment have been proposed for the management of bone defects following resection or trauma. Usually, larger defects are treated with vascularized fibula grafts. Alternative treatment approaches that avoid donor site morbidity would be advantageous. Bone tissue engineering seeks to regenerate osseous tissue using a combination of biomaterials, bioactive molecules, and stem cells. The source of stem cells for tissue engineering depends on the requirement of structure that is to be replaced.

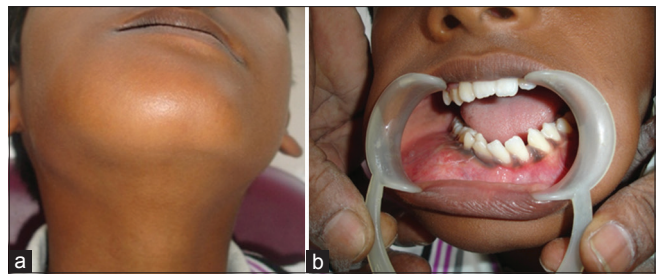
Sammartino *et al.*<sup>[5]</sup> also advocate conservative treatment for larger ameloblastoma to avoid cosmetic, functional, and esthetic problems that occur in radical resection. Even though enucleation and curettage of ameloblastoma lead to unacceptable recurrence rate of about 55–90%, they suggest that those cortical perforations were treated by resection with overlying soft tissue.

Khakoo *et al.*<sup>[6]</sup> have demonstrated an anti-tumorigenic effect of human mesenchymal stem cell in a patient of Kaposi's sarcoma. We also observed the anti-tumorigenic effect. d'Aquino *et al.*<sup>[7]</sup> have used human DPSCs in bone tissue formation. Kim *et al.*<sup>[8]</sup> used autologous human bone marrow mesenchymal stem cells and autogenous bone graft to successfully regenerate a mandibular defect in a case of plexiform ameloblastoma. Following reconstruction, they placed osteo-integrated dental implant-supported prosthesis to rehabilitate.

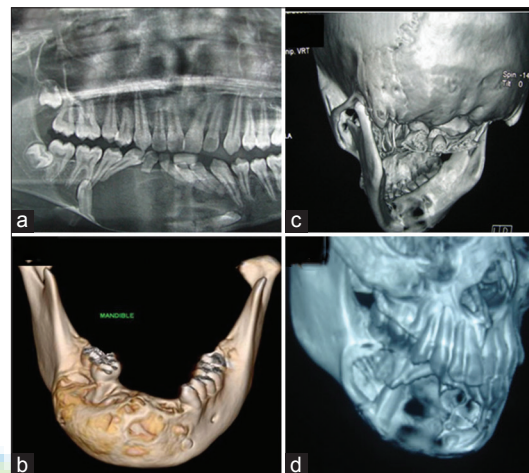
Sándor *et al.*<sup>[9]</sup> successfully regenerated a 10 cm anterior mandibular ameloblastoma resection defect. They reproduced the original anatomy using expanded autologous adipose stem cells with  $\beta$ -tricalcium phosphate and bone morphogenic protein. They also rehabilitated the patient with dental implant-supported prostheses. These authors went on further to report 13 cranio-maxillofacial defects using that method of reconstruction. Manimaran *et al.*<sup>[10]</sup> successfully treated two cases of osteoradionecrosis without jaw resection, where conventional methods had failed. One case was treated with autologous bone marrow concentrate and another case was treated with DPSC mixed with  $\beta$ -tricalcium phosphate. These authors report successfully regenerated posterior mandibular ameloblastoma resection defect using allogeneic cord stem cells.

## CONCLUSION

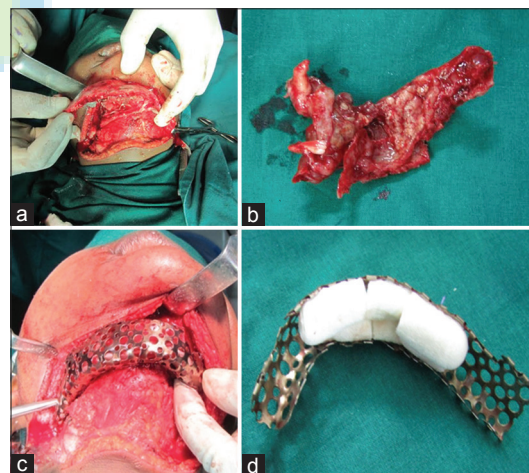
This case report demonstrates the potential use of DPSCs and stem cells of the SVF of the buccal fat pad for cases with major mandibular defects. Moreover, it was to provide a safe and predictable reconstruction without the major morbidity associated with the extensive harvesting of a large



**Figure 1:** Clinical image (a) extraoral swelling. (b) intraoral swelling



**Figure 2:** Preoperative (a) orthopantomogram (b) computed tomography-mandible (labial expansion) (c) computed tomography-mandible lingual perforation (d) computed tomography-lateral view of the Mandible



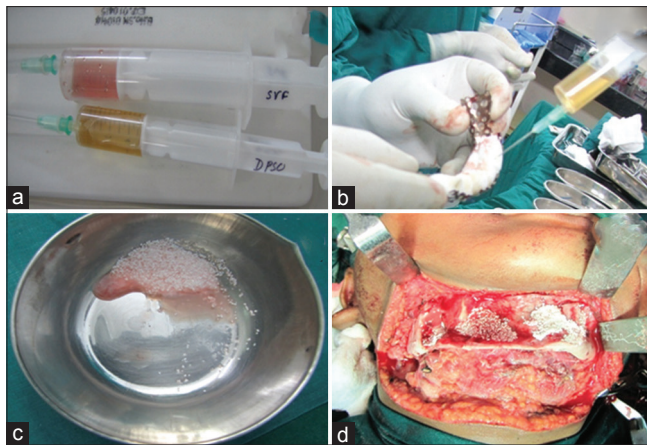
**Figure 3:** (a) Curetting the lesion (b) removed mandible (c) placing the mesh (d) mesh carrying the SyboGrafts

autogenous bone graft. However, the authors propose a larger case series to study the future implications and potential of this technique.

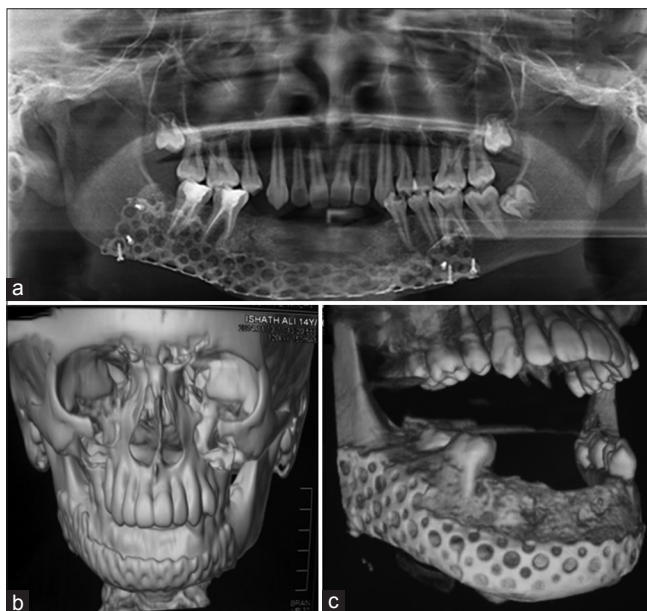
## Acknowledgment

The authors would like to thank Dr. D. Avinash Gandhi Ph.D., Scientific Coordinator, Mother Cell Regenerative Centre, for dental pulp and stromal vascular fraction processing.





**Figure 4:** Intraoperative procedure (a) syringes with stromal vascular fraction and dental pulp stem cell (b) placing stromal vascular fraction and dental pulp stem cell in SyboGraft. (c) Stromal vascular fraction mixed with granules. (d) Placing mixed granules over lingual cortex



**Figure 5:** Postoperative (a) orthopantomogram at 10<sup>th</sup> month (b) computed tomography mandible at 10<sup>th</sup> month AP view (c) Mandible lateral view

### Financial support and sponsorship

This study was supported by the research and training funds of the Laboratory of Cell Culture, Mother Cell Regenerative Centre Pvt. Ltd., Trichy, Tamil Nadu, India.

### Conflicts of interest

There are no conflicts of interest.

## REFERENCES

- Hertog D, van der Waal I. Ameloblastoma of the jaws: A critical reappraisal based on a 40-years single institution experience. *Oral Oncol* 2010;46:61-4.
- Sándor GK, Tuovinen VJ, Wolff J, Patrikoski M, Jokinen J, Nieminen E, *et al.* Adipose stem cell tissue-engineered construct used to treat large anterior mandibular defect: A case report and review of the clinical application of good manufacturing practice-level adipose stem cells for bone regeneration. *J Oral Maxillofac Surg* 2013;71:938-50.
- Antonoglou GN, Sándor GK. Recurrence rates of intraosseous ameloblastomas of the jaws: A systematic review of conservative versus aggressive treatment approaches and meta-analysis of non-randomized studies. *J Craniomaxillofac Surg* 2015;43:149-57.
- Zuk PA, Zhu M, Ashjian P, De Ugarte DA, Huang JJ, Mizuno H, *et al.* Human adipose tissue is a source of multipotent stem cells. *Mol Biol Cell* 2002;13:4279-95.
- Sammartino G, Zarrelli C, Urciuolo V, di Lauro AE, di Lauro F, Santarelli A, *et al.* Effectiveness of a new decisional algorithm in managing mandibular ameloblastomas: A 10-years experience. *Br J Oral Maxillofac Surg* 2007;45:306-10.
- Khakoo AY, Pati S, Anderson SA, Reid W, Elshal MF, Rovira II, *et al.* Human mesenchymal stem cells exert potent antitumorigenic effects in a model of Kaposi's sarcoma. *J Exp Med* 2006;203:1235-47.
- d'Aquino R, De Rosa A, Laino G, Caruso F, Guida L, Rullo R, *et al.* Human dental pulp stem cells: From biology to clinical applications. *J Exp Zool B Mol Dev Evol* 2009;312B: 408-15.
- Kim BC, Yoon JH, Choi B, Lee J. Mandibular reconstruction with autologous human bone marrow stem cells and autogenous bone graft in a patient with plexiform ameloblastoma. *J Craniofac Surg* 2013;24:e409-11.
- Sándor GK, Numminen J, Wolff J, Thesleff T, Miettinen A, Tuovinen VJ, *et al.* Adipose stem cells used to reconstruct 13 cases with cranio-maxillofacial hard-tissue defects. *Stem Cells Transl Med* 2014;3:530-40.
- Manimaran K, Sankaranarayanan S, Ravi VR, Elangovan S, Chandramohan M, Perumal SM. Treatment of osteoradionecrosis of mandible with bone marrow concentrate and with dental pulp stem cells. *Ann Maxillofac Surg* 2014;4:189-92.